

Immediate versus delayed single implant placement: case studies

Dr H S Elmanharawy takes a careful look at the issues surrounding immediate implant loading

Case 1: Immediate placement and immediate loading of Ankylos implant in the UR2 region

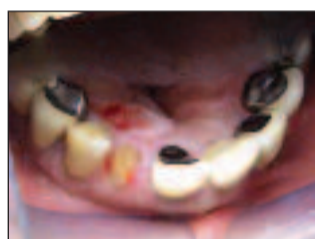

Figure 1: Patient before treatment

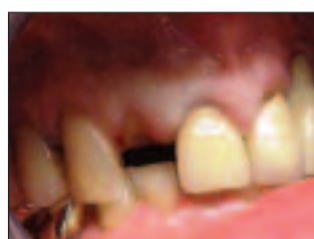

Figure 2: Patient before treatment

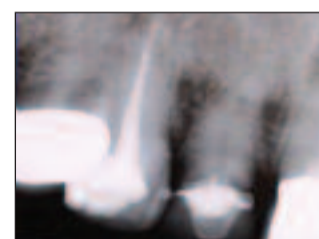


Figure 3: Pre-operative radiograph

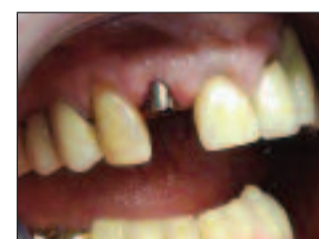

Figure 4: Immediate implant placed and temporary abutment secured

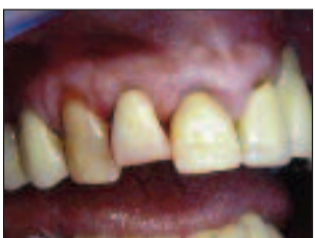

Figure 5: Temporary acrylic crown cemented to the temporary abutment



Figure 6: Immediate post-op radiograph

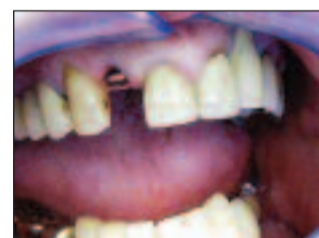

Figure 7: Three months post-placement with sulcus former in place

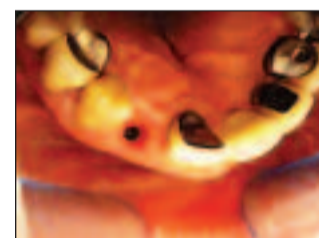


Figure 8: Healthy gingival collar at impression stage

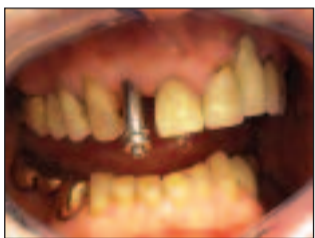

Figure 9: Open tray impression for definitive implant-supported restoration

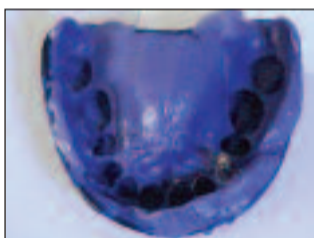


Figure 10: Open tray impression

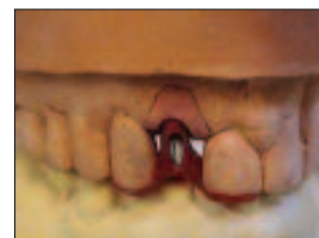

Figure 11: Definitive abutment and transfer jig on working model

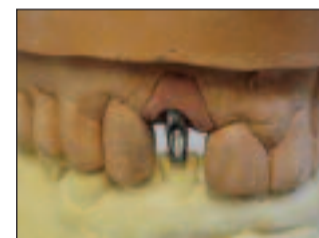

Figure 12: Definitive abutment

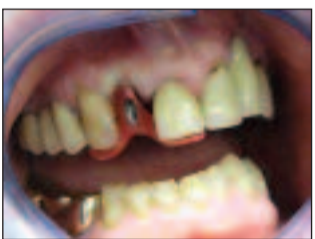

Figure 13: Abutment secured to implant, accurately positioned by the jig

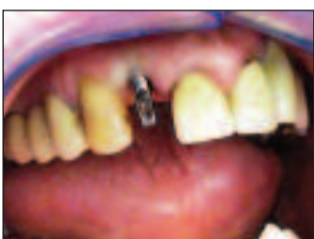

Figure 14: Definitive abutment secured to the implant

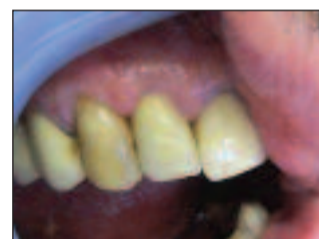

Figure 15: Definitive crown



Figure 16: Final radiograph of the definitive implant-supported restoration

Today, immediate implant placement into fresh extraction sockets, first introduced by Schulte *et al* in the late seventies¹, is considered to be a predictable procedure. A series of well-controlled studies by Schwartz, Arad *et al* investigated the influence of immediate implantation survival rates and comprised of a large number of immediately-placed implants over seven years. These suggested that immediately-placed implants are as predictable as those implants placed in completely healed extraction sites, and that immediate implantation does not carry additional morbidity.^{2,3}

There are, however, some important factors to be considered in order to ensure this predictability, as well as long-term acceptable aesthetic and functional outcomes.

Available bone height should be confirmed by careful radiological examination. Ideally, 2-3mm of healthy, good quality dense bone apical to the socket should be present in order to ensure good primary stability. A CT scan is a very helpful tool in assessing bone quality and density, measured in Hounsfield units.

The extraction socket should be free from acute pathology. This can be confirmed by preoperative radiographs and the absence of acute symptoms associated with the tooth to be extracted. The extraction socket should be examined carefully following extraction, in order to ensure intact walls. This can be performed using a ball-ended periodontal probe. Detected bone defects may require either guided bone regeneration or a bone grafting procedure, and the patient should be pre warned about this possibility.

Some animal studies, with their obvious limitations, indicated that chronic well-contained asymptomatic lesions can be curetted before implants are immediately placed, provided

that no bone defects are present and that the presence of these lesions does not compromise healing or osseointegration of the immediately placed implants.⁴

Soft tissue contour and volume should be sufficient to ensure acceptable profile and gingival health of the completed implant-supported restoration. The site should be free from periodontal disease to ensure stability of the soft and hard tissue around the implant. The crestal and papillary bone level approximal to the site of the implantation should be stable, as this in turn will be dictating the stability of the approximal papillary height around the definitive restoration.

Different teeth exhibit different anatomy, and this fact makes some teeth better candidates than others for immediate implantation. The bulbous contour of canine teeth roots renders them more likely to exhibit some labial dehiscence. Lower central and lateral incisors have fine roots that may result in labial perforation.

Several animal studies have demonstrated that the implant's design and surface characteristics have a significant influence on bone reaction during healing of the immediately placed implants.

A consensus committee report prepared by Ganeles and co-workers reviewed the available literature published predominantly in refereed journals and concluded that most of the reviewed studies demonstrated lower success rate with machined surface implants, particularly in poor quality bone.⁵

Implants with a sparse thread pattern have been also found to increase success rate of immediately placed implants. Few investigators have directly compared the integration rates of roughened, threaded surfaces with those of machined surfaces. Glauser and co-workers noted a significant increase in success

Case 2: Immediate implant placement and delayed loading U/R5

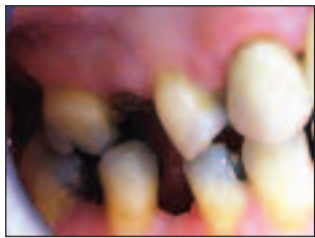

Figure 1: Patient before treatment

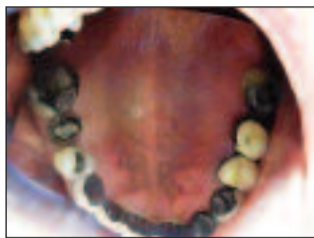

Figure 2: Patient before treatment

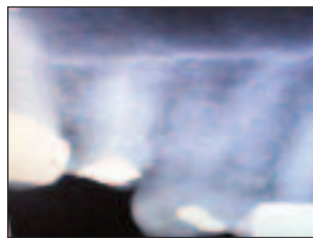

Figure 3: Pre-operative radiograph

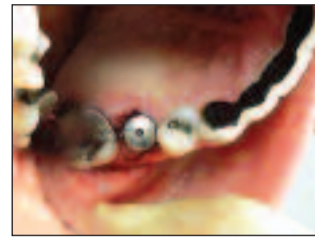

Figure 4: Immediate implant placed and sulcus former secured to implant

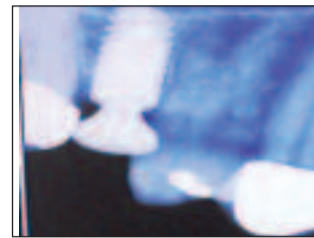


Figure 5: Immediate post-op radiograph with implant in place

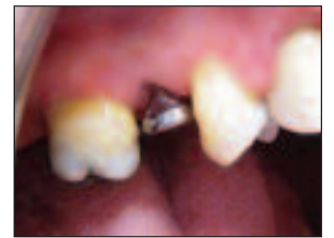

Figure 6: Healing at eight weeks following implant placement (labial view)

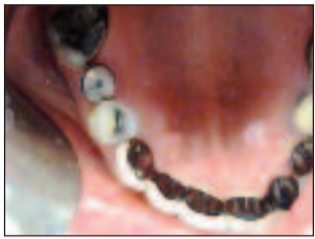

Figure 7: Healing at eight weeks following implant placement (occlusal view)

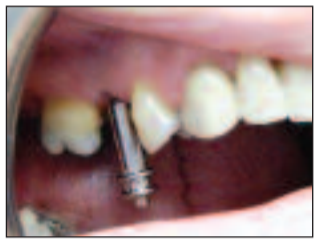

Figure 8: Open tray impression for definitive implant-supported crown

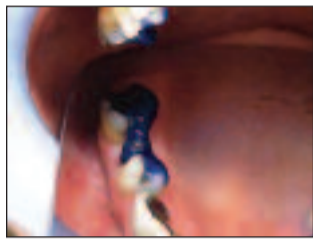

Figure 9: Definitive abutment secured with and accurately positioned by transfer jig

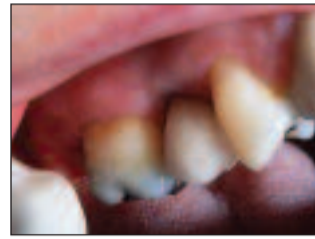

Figure 10: Implant-supported full porcelain crown

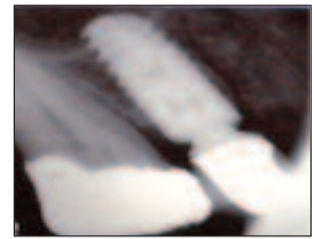


Figure 11: Final radiograph of the definitive implant-supported restoration

Case 3: Immediate implant placement and delayed loading U/L4

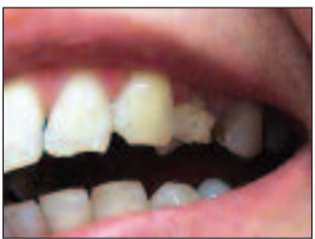

Figure 1: Patient presenting with a remaining root U/L4 region

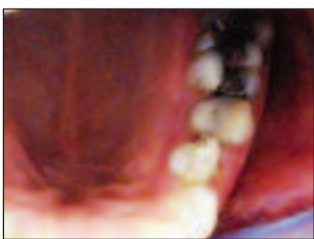

Figure 2: Occlusal view of the remaining root




Figure 3: Pre-op periapical radiograph

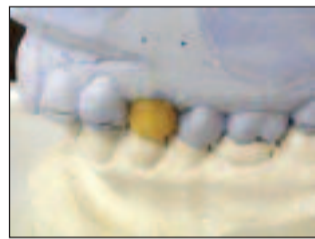


Figure 4: Wax-up of the tooth to be treated



Figure 5: Surgical stent

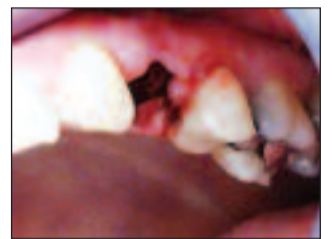

Figure 6: U/L4 atraumatically removed

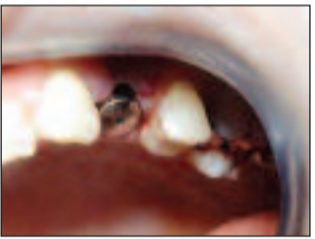

Figure 7: Ankylos implant installed and sulcus former secured to implant

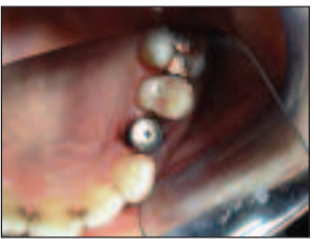

Figure 8: Occlusal view of the immediately placed implant

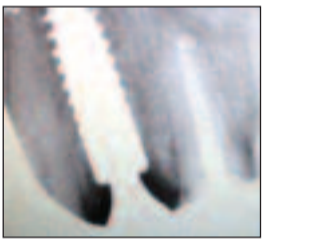


Figure 9: Immediate post-op radiograph

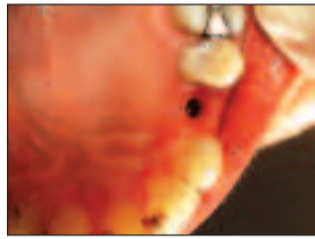

Figure 10: Healing after three months

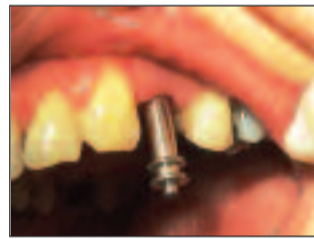

Figure 11: Impression coping secured at impression stage

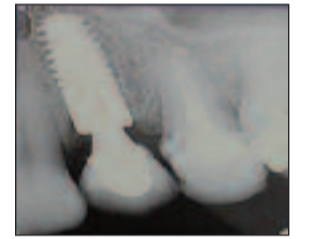

Figure 12: Post cementation radiograph

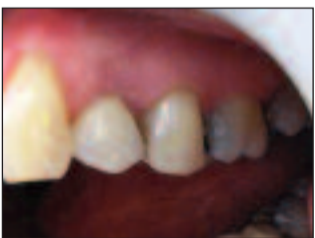

Figure 13: Final restoration

rate when using threaded implants with rough surfaces compared to machine-surfaced implants, and the difference was particularly striking when evaluating both types of implants in poor quality bone.⁶

Extraction

The importance of clinical and radiological examinations of the tooth to be extracted cannot be over-stressed. These offer valuable information regarding potential difficulties, such as unfavourable root patterns and the presence of pathology.

Extraction should be performed atraumatically, using periostomes and fine peaked elevators specially designed for this purpose. Difficult teeth or roots can be sectioned by high-speed drills and elevated separately. A gentle finger pressure on the buccal plate during elevation can minimise micro fractures of the bony plate.

Where possible, full thickness mucoperiosteal flaps should be avoided in order to maintain blood supply to the healing socket. Following extraction, the socket should be irrigated with sterile saline and thoroughly inspected for fragments or defects.

Implant placement

A surgical stent, based on a diagnostic wax-up, is often used to assist with implant positioning. In the anterior maxillary region, the site is usually developed slightly in a more palatal direction to that of the extracted tooth in order to avoid cortical plate perforation and improve primary stability, as well as to obliterate most of the extraction socket.

A pilot drill is used to establish the centre of the osteotomy. This pilot osteotomy will be gradually enlarged to achieve the diameter of the implant to be placed. This can be performed by using irrigated drills, osteotomes, or bone spreaders. In the posterior maxilla osteotomes are usually preferred in order to

improve bone density and bone/implant contact. The use of osteotomes and bone spreaders will also offer gradual and controlled site enlargement, thus minimising the risk of perforation, especially when the procedure is performed with no flap reflection i.e. blindly.

During site enlargement, the bone plates should be continuously inspected for perforation and gentle finger pressure on the labial plates should be maintained. The desired implant should then be inserted using the appropriate inserting device. Manual placement offers controlled torque, as well as the advantage of 'feeling' primary stability as the implant is introduced. The desired depth of the inserted implant will be dictated by the required aesthetic profile based on the protocol of the system used.

If immediate loading is planned, no closure is required. If however, there are doubts regarding primary stability, or if the occlusion is not favourable, then wound closure would be required. If primary closure cannot be achieved – as in the case of wide sockets and limited soft tissue – occluding membranes or soft tissue grafts can be considered.

Risks and benefits of immediate implant placement

Placement of dental implants into fresh extraction sockets offers a number of significant advantages.

Without the support provided by functioning teeth or implants, extraction sockets undergo catabolic phase as a part of the remodelling process. This results in varying amounts of atrophy after tooth removal. Recession of the mucosal and gingival tissues accompanies bone remodelling. As a result, achievement of superior aesthetics becomes more difficult, particularly in the aesthetic zone.

Immediate placement offers minimal changes to the healing bone and soft tissues, leading to better aesthetic and functional outcomes.

Furthermore, implants in fresh extraction sockets can be placed in almost the same position as the extracted tooth, facilitating the positioning of the final restoration within the same prosthetic envelope without the need for severe angulation of the abutment or fabrication of telescopic copings. This results in superior aesthetic and functional results.

Finally, eliminating the standard wait for primary healing of the soft and hard tissues significantly shortens the overall treatment time and the interval during which the patient must live in a transitional state with or without teeth. The reduction of the number of surgical appointments and associated surgical trauma as well as less overall treatment costs increases patients' acceptance of implant treatment.⁸

Immediate implant placement requires some strict parameters for success and should be decided upon following a careful planning stage. The ideal situation for immediate implant placement is where the infection-free, intact socket can be obliterated almost entirely by the implant. With increasing gap size between the implant and the socket, the amount of bone to implant contact is reduced.

Situations where single teeth need to be replaced by means of an immediate implant depend on the adjacent teeth to sustain the level of bone. In situations where multiple teeth need to be extracted and immediately replaced, some concerns regarding the ability to sustain bone levels may be raised. Loss of bone between the implants may result in loss of interdental papillae. This may result in having to embark on adjunctive hard tissue/soft tissue grafting/augmentation procedures that defy the object of performing immediate placement in the first place.

Anatomical variations and different root patterns of different teeth can result in some difficulties with immediate implantation. The limited vertical height caused by the presence of the maxillary sinus in the posterior maxilla and

Case 4: Immediate implant placement and immediate loading U/R5



Figure 1: Patient presenting with a remaining root

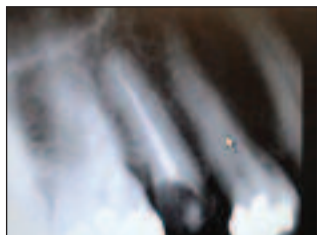


Figure 2: Periapical radiograph at U/R5

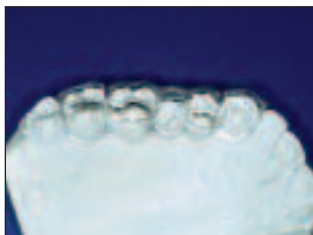

Figure 3: Sectional surgical stent based on diagnostic wax-up

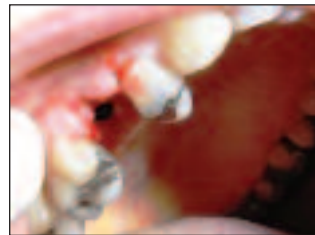

Figure 4: Difficult extraction of U/R5 root

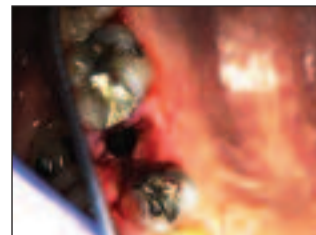


Figure 5: U/R5 socket (occlusal view)

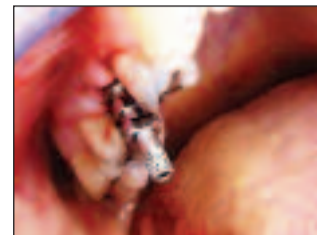

Figure 6: Implant placed with impression coping secured for first stage impression

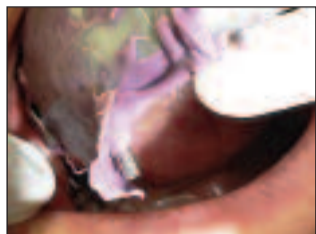


Figure 7: Open tray first stage impression

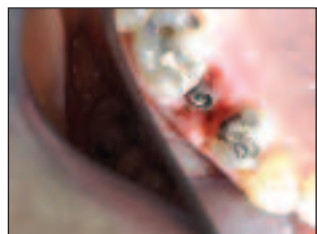

Figure 8: Temporary abutment secured to implant

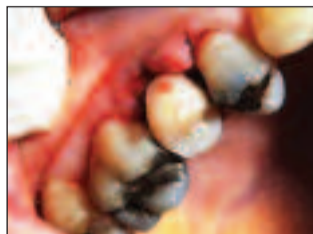

Figure 9: Temporary acrylic crown secured to the abutment

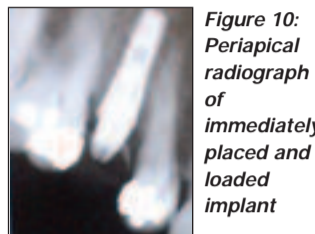


Figure 10: Periapical radiograph of immediately placed and loaded implant

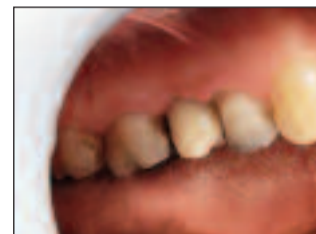

Figure 11: U/R 5 six weeks following placement

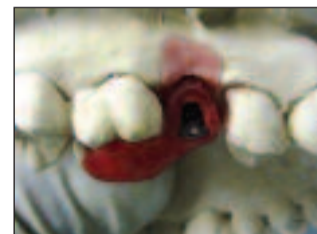

Figure 12: Definitive abutment and transfer jig

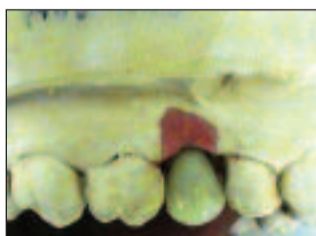

Figure 13: Definitive implant supported crown

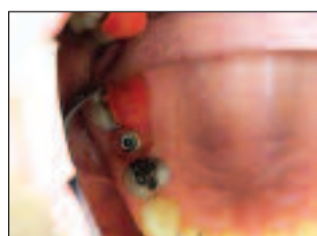

Figure 14: Definitive abutment secured to implant

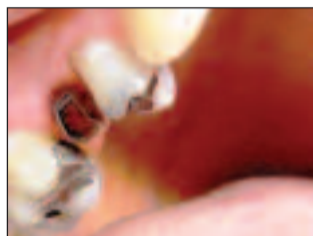

Figure 15: Abutment secured to implant

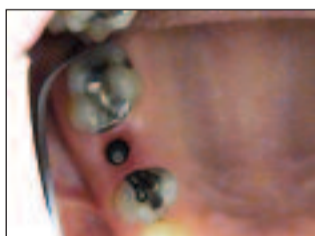

Figure 16: Occlusal view of the definitive abutment

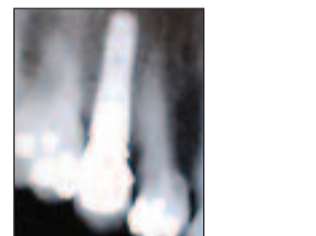

Figure 17: Radiograph of the definitive restoration

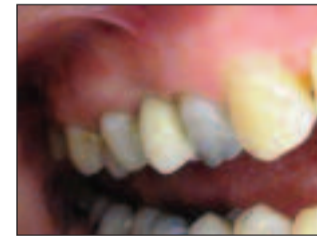

Figure 18: Implant supported definitive crown U/R5

inferior dental nerve in the posterior mandible, coupled with the presence of wide sockets, may tempt the clinician to use larger diameter but shorter implants, thus relying on engaging the socket walls in order to achieve sufficient primary stability. This would in turn carry the risk of perforation or placing implants outside the pre-planned prosthetic envelop.


References:

1. Wilson G, Schenk R, Buser D, Cochran D (1998). Implants placed in immediate extraction sites: A report of histologic and histometric analysis of human biopsies. *Int J Oral Maxillofac Implants*, **13**: 333-341.
2. Schwartz - Arad D, Caushu G (1997). The ways and wherefores of immediate implantation: a critical review. *J Periodontol*, **68**: 915-923
3. Schwartz - Arad D, Caushu G (1997). Placement of implants into fresh extraction sites: 4-7 years retrospective evaluation of 95 immediate implants. *J Periodontol*, **68**: 1110-16
4. Novaes AB Jr, Guaracilei MV, Jr et al (1998). Immediate implants placed into infected sites. A histomorphometric study in dogs. *Int J Oral Maxillofac Implants*, **13**: 422-27
5. Ganeles J, Wismeijer D (2004). Early and immediately restored and loaded dental implants for single tooth and partial arch applications. *Int J Oral Maxillofac Implants*, **19**(Suppl): 92-102
6. Glauser R, Lundgren AK, Gottlow J, et al (2003). Immediate occlusal loading of Branemark Ti Unite implants placed predominantly in soft bone. One-year results of a prospective clinical study. *Clin Implant Dent Relat res*, **5**(Suppl 1): 47-55
7. Sethi A, Kaus T (2005). Practical Implant Dentistry: diagnostic, surgical, restorative, and technical aspects of aesthetic and functional harmony. Quintessence Publishing Co. Ltd: 75-79
8. Gomez-Roman G, Kruppenbacher M, Weber H (2001). Immediate post extraction implant placement with root-analog stepped implants: Surgical procedure and statistical outcome after 6 years. *Int J Oral Maxillofac Implants*, **16**: 503-513

The laboratory work was carried out by:

Case 1:
Thomas Hardt
Senior technician
Rubeling Dental Labor
27580 Bremhaven
Germany

Cases 2, 3, and 4:
Keith Shrubbs
Master technician
SBO Dental Lab
120a Marylebone Lane
London W1U 2QG



Dr H S Elmanharawy BDS LDS RCPS (Glasg.) DPDS (Brist.) MSc (OMFS.Lond) Dip Imp Dent RCS (Eng.), Specialist Oral Surgeon is registered by the General Dental Council as a specialist in oral surgery and has been in the practice of all aspects of implant dentistry for the past 15 years. He is the clinical director of the Cottage Dental & Implant Clinic in Wootton Bassett, where he accepts referrals for oral surgical and implant procedures from local colleagues.